

# NOVICE GUIDE TO POINT OF CARE ULTRASOUND



## TRANSDUCERS



Figure 1.1 Linear Probe



Figure 1.2 Curvilinear Probe




Figure 1.3 Cardiac Probe

## PROBE ORIENTATION

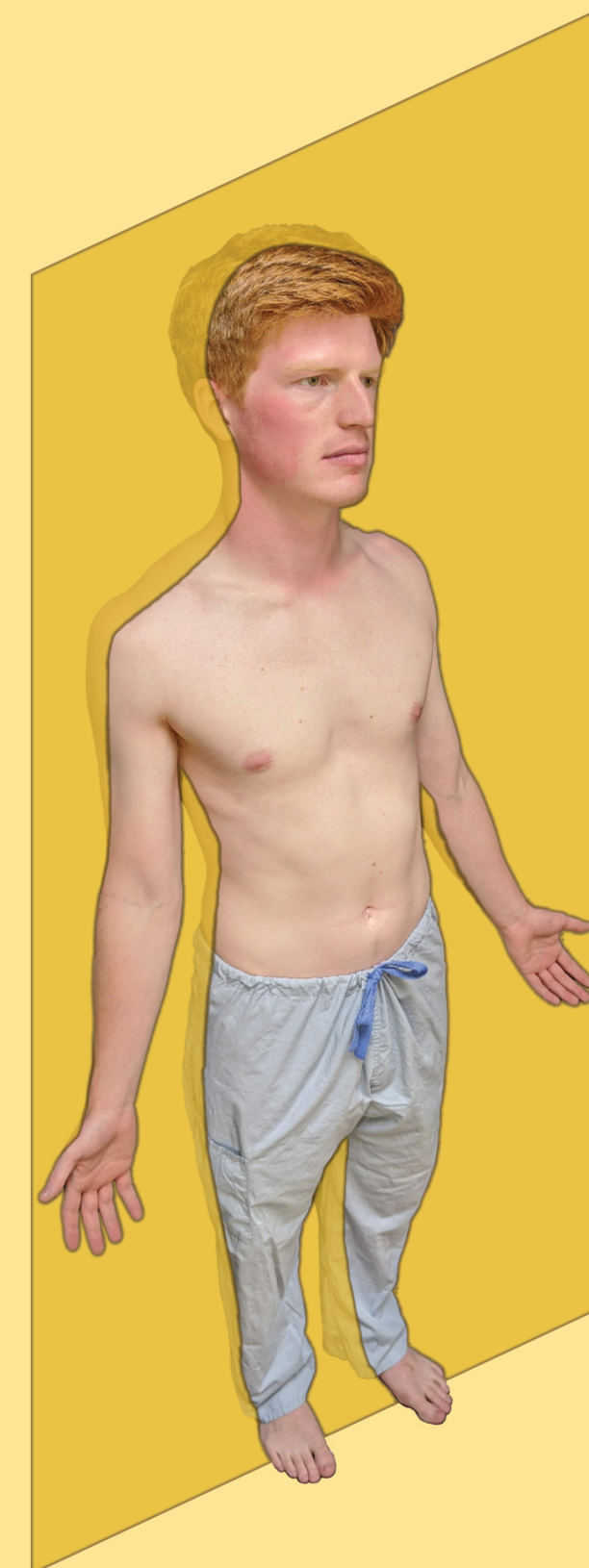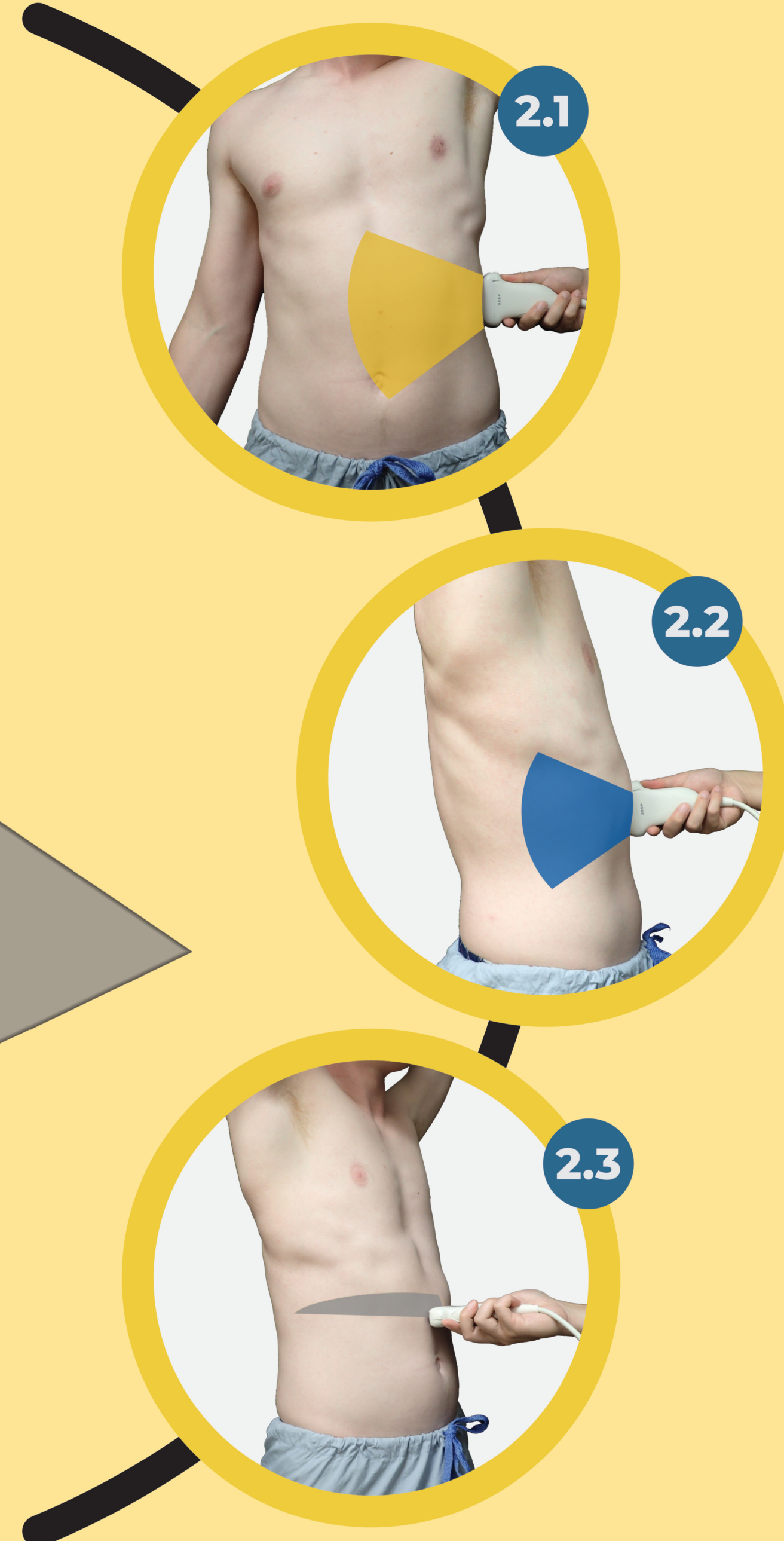


Figure 2.1 Coronal Plane

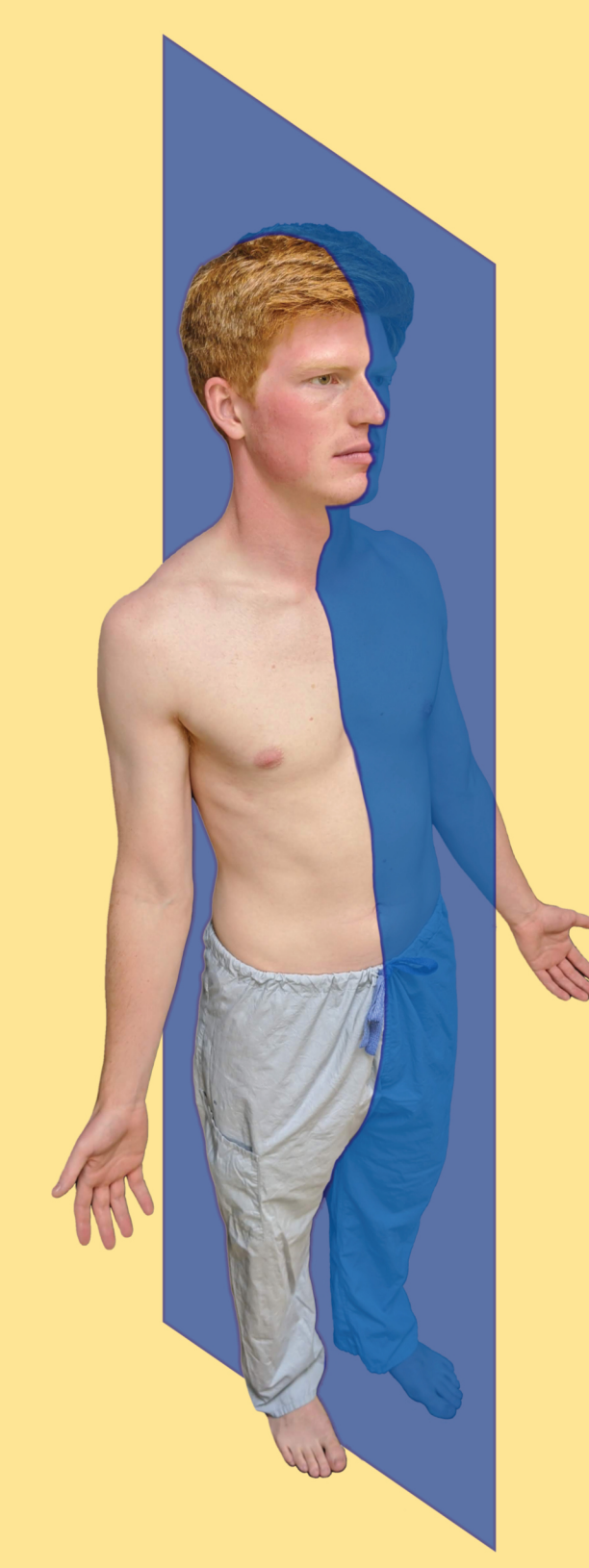

Figure 2.2 Sagittal Plane




Figure 2.3 Transverse Plane

## SCAN QR CODES FOR INSTRUCTIONAL VIDEOS

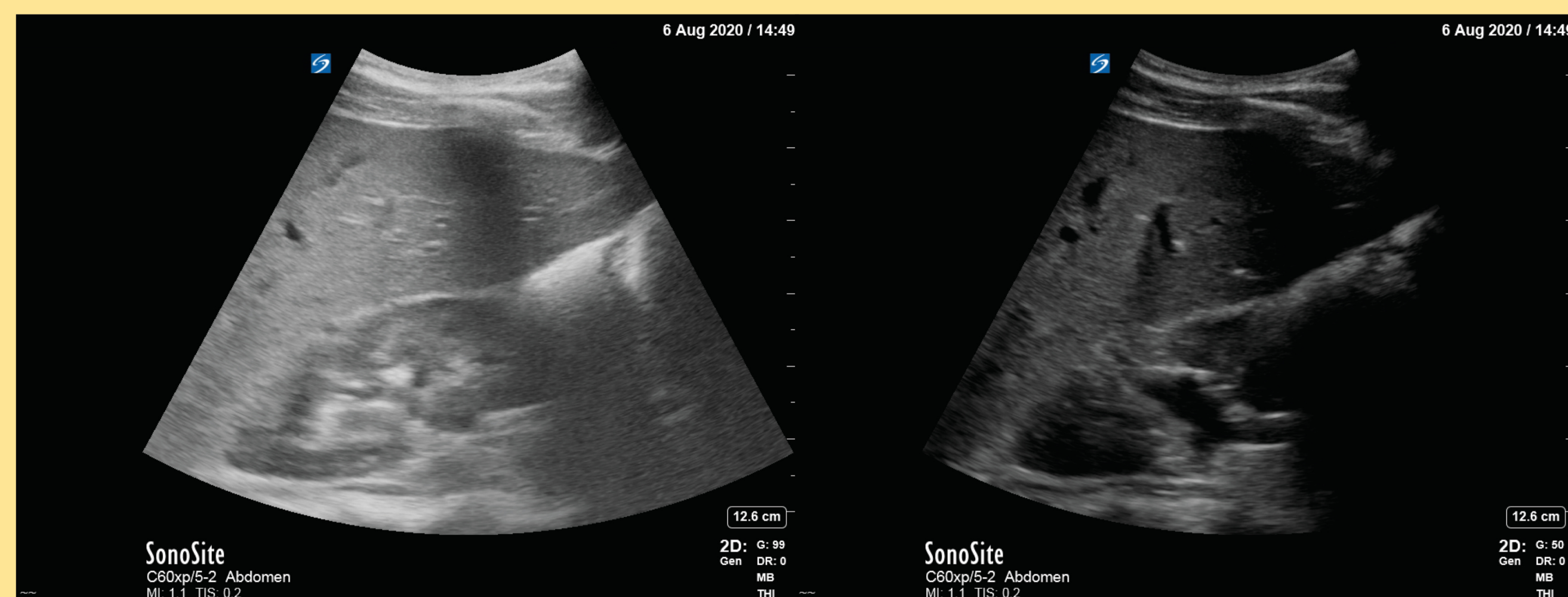


Figure 3.1 Gain An image of the hepatorenal interface. The image on the left has been adjusted with high gain, while the image on the right is normal gain. Gain allows the operator to increase the brightness of an image.

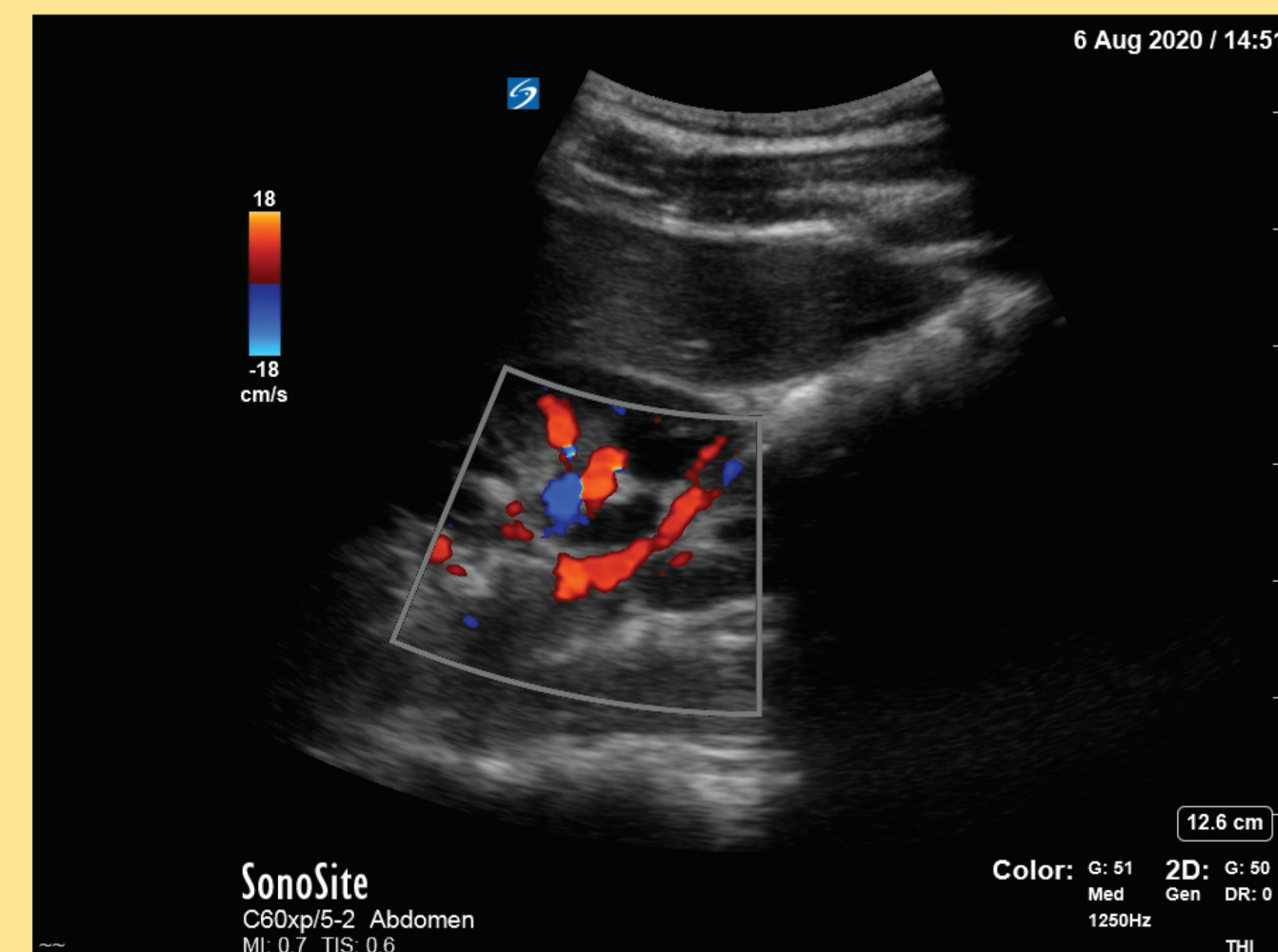


Figure 3.2 Doppler Features the doppler setting seen on most ultrasound machines. Blue indicates movement away from the probe, while red indicates movement towards the probe.

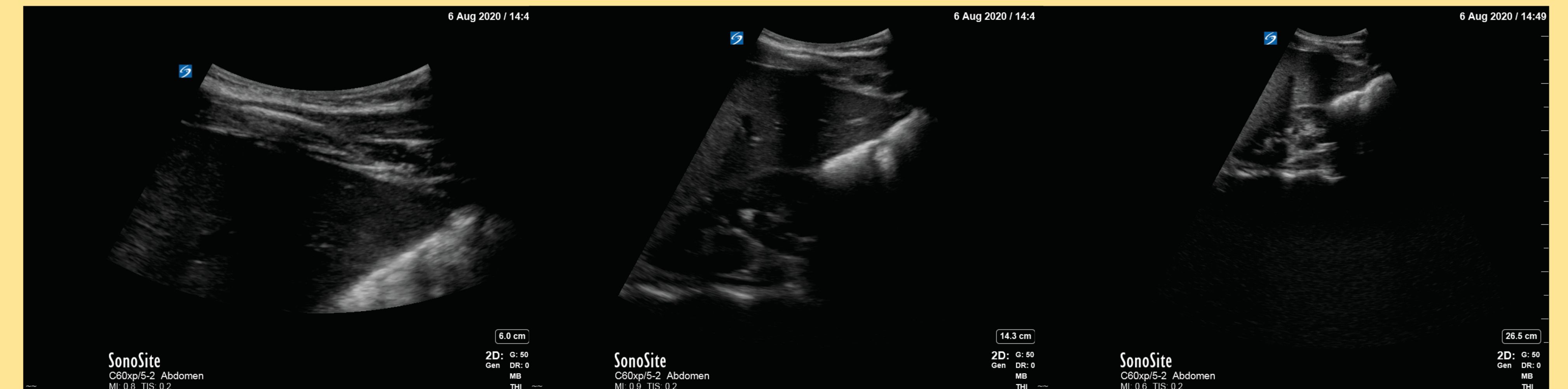


Figure 3.3 Depth A series of images of the hepatorenal interface. The depth function was altered to show the influence of depth on the field of view.